



# Olgu Sunumu

---

*Dr.Serhan Tanju*  
*İstanbul Üniversitesi İstanbul Tıp Fakültesi*  
*Göğüs Cerrahisi Anabilim Dalı*



44 y,E

n 2005


n Öksürük, sol yan  
ağrısı

# Toraks BT

2005

*Sol plevral efüzyon  
Non-spesifik antibiyoterapi  
klinik regresyon*





- n Torasentez
  - n Eksuda
  - n Sitoloji negatif
  - n Plevra biyopsisi
    - n Vagal senkop
  
- n Sol Torakoskopik plevra –akciğer biyopsisi
  - n Mezotelioma (epiteloid)

# Mezotelioma

## Evreleme


---


- n PET-CT
- n Kranial / Batın MR
  - n Ekstratorasik lezyon saptanmadı.
- n Mediastinoskopi

PET CT

Kasım 2007

---





n Mediastinoskopi

n 2R (-)

n 4R (-)

n 7(-)

n 2L (-)

n 4R (-)

n IMIG

n T2 N0 M0

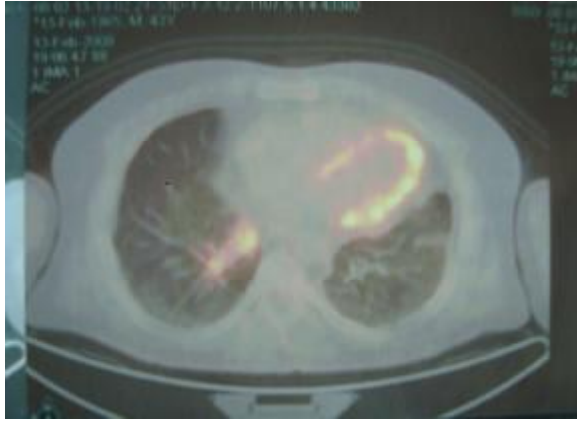
n SFT

n FEV1:2570 (%73)


n FVC:3550 (%84)

Ekstraplevral plöroptomonektomi


Şubat 2008




Non-spesifik antibiyoterapi



- n Balgam sitolojisi
- n Kültür antibiyogram
- n Ampirik antibiyoterapi



- n Persiste eden efüzyon
- n Lezyon silinmiş;



n Konsey

n Karar;

n Neoadjuvant KT +/- PD

n RT



# Onkolojik tedavi

---

- n Kemoterapi

- n Cisplatin

- n 75mg/m<sup>2</sup>

- n Pemetrexet

- n 500mg/m<sup>2</sup>

- n D1 Q21



# Toraks BT

---




# Operasyon

---

n Parietal plevrektomi, dekortikasyon

# Postop Toraks BT






# Radyoterapi

---

n RT

- n Subklinik hastalık bölgelerine
- n 45 GRY/50GRY



# Post op 6.ay toraks bt

---